

2024

## Mesioclusion: A Review of Treatment Approaches

Kasem Ahmed Abeas

*Department of Orthodontics, College of Dentistry, University of Babylon, Babil, Hilla, Iraq,*  
aakasem2@gmail.com

Follow this and additional works at: <https://hucmsj.hilla-unc.edu.iq/journal>

---

### How to Cite This Article

Abeas, Kasem Ahmed (2024) "Mesioclusion: A Review of Treatment Approaches," *Hilla University College Journal For Medical Science*: Vol. 2: Iss. 3, Article 1.

DOI: <https://doi.org/10.62445/2958-4515.1025>

This Review is brought to you for free and open access by Hilla University College Journal For Medical Science. It has been accepted for inclusion in Hilla University College Journal For Medical Science by an authorized editor of Hilla University College Journal For Medical Science.

## REVIEW

# Mesiocclusion: A Review of Treatment Approaches

Kasem Ahmed Abeas

Department of Orthodontics, College of Dentistry, University of Babylon, Babil, Hilla, Iraq

## Abstract

Mesiocclusion or Class III malocclusion is one of the dental disturbances that represents the magnitude and complexity of the entire problem of malocclusion. It is of special interest to the orthodontist because it offers a therapeutic challenge. The aim of this study is to review the common treatment options for Class III malocclusion and determine which approach is superior. Numerous studies have recommended intervention at an early stage, such as during the deciduous dentition or prepubertal growth phase. Early treatment of skeletal Class III malocclusion can be achieved by several appliances including Bionator, Frankle, chin cup, face mask. Orthopedic protraction of the maxilla is a popular treatment modality, although it has some limitations. In addition, rapid maxillary expansion has been recommended as a routine component of treatment, even in the absence of maxillary constriction. Although there are multiple treatment possibilities, the protraction face mask is the common and most effective treatment option for Class III malocclusion before maxillary suture maturation is encountered, during the early mixed dentition years.

**Keywords:** Class III malocclusion, Orthodontic appliances, Treatment options

## 1. Introduction

Class III is one of those disturbances of the dentition which represents the magnitude and complexity of the entire problem of malocclusion [1]. Dentoskeletal Class III malocclusions are one of the greatest challenges to the orthodontists due to the interaction of both environmental and genetic etiological factors [2]. The etiology of Class III malocclusion is multifactorial, with genetic, ethnic, environmental, and habitual components [3]. Etiologic factors for Class III malocclusions include a wide spectrum of skeletal and dental compensation components [4]. The condition might be characterized by mandibular prognathism, maxillary retrognathism, retrusive mandibular dentition, protrusive maxillary dentition, and a combination of the above [5]. Class III problems may arise due to deficient growth of maxilla in the downward and forward direction and more forward growth or reduced downward growth of mandible. Hence, a hypodivergent growth pattern accentuates the Class III problem due to more growth rotation of the mandible in the upward and forward direc-

tion, while a vertical growth pattern alleviates it due to downward and backward rotation, provided that excessive facial height does not become the problem instead [6]. The prevalence of angle class III malocclusion varies greatly among and within populations, with the greatest incidence being seen among Asian people [4]. Different ethnic groups exhibit different prevalence rates of Class III, with different methods of classification being used. The prevalence rate was reported to be around 1–3% in the Caucasians and around 13–14% among the Chinese and Japanese [7–12].

The Class III malocclusion is rare compared to other types of malocclusion, with an incidence of possibly less than 5%. It is of special interest to the orthodontist because it offers a therapeutic challenge. It is usually a progressive type of malocclusion, which makes it difficult for the clinician to protect the future growth of such patients both magnitude and direction. Even after achieving good results and following the cessation of active treatment, these patients have a high tendency to relapse. This has been attributed to the reappearance of the adverse growth vectors causing

Received 25 March 2024; accepted 29 July 2024.  
Available online 20 September 2024

E-mail address: aakasem2@gmail.com (K. A. Abeas).

<https://doi.org/10.62445/2958-4515.1025>

2958-4515/© 2024, The Author. Published by Hilla University College. This is an open access article under the CC BY 4.0 Licence (<https://creativecommons.org/licenses/by/4.0/>).

the mandible to grow further forward than it would normally grow [13]. Over the years, several interceptive treatments for Class III dentoskeletal malocclusions have been proposed in growing patients [14, 15].

As the concept of the growth and its prediction became more clear, treatment of class III malocclusion also improved. Still, the treatment of class III malocclusion is challenging. Although various treatment modalities are available, which aim at the correction of class III malocclusion during the growth period, these have proved unsuccessful in maintaining the result for long time. Retention appliances are required to be worn until growth is complete. And relying on the patient to cooperate over long period and extended treatment protocol is a potential problem in achieving successful, stable treatment result. Surgical intervention may still be needed in few cases. The newer and more advanced treatment procedures available to us today offer hope for patients, so that psychological and morphological setbacks are avoided and lessened during the formative years of life [13]. The early treatment can help to promote a favorable skeletal equilibrium correcting the negative overjet, enhancing the maxillary growth and limiting the mandibular one, controlling and/or eliminating the environmental factors, and minimizing the incisor compensation [16–18]. Some authors support the benefits of early treatment and point to the disadvantages of a long treatment time while waiting for the skeletal maturation of a child before sending him or her for orthognathic surgery [19].

This review highlights the best timing and treatment options for class III malocclusion that develops in growing patients.

## 2. Definition of class III malocclusion

In terms of angle classification, a class III malocclusion is one in which the lower molar is mesially positioned relative to the upper molar, with no specifications with regard to the line of occlusion [20]. According to the British Standard Institute (BSI), the class III incisor relationship is defined as one in which the lower incisor edge lies anterior to the cingulum plateau of the upper incisors, the overjet is reduced or reversed [19] Fig. 1.

## 3. Etiology

Similar to most of the malocclusions and dentofacial deformities, the etiology of Class III malocclusion is multifactorial. It results from a distortion of normal development, rather than from any pathological process. Expressions of Class III malocclusion are results of interaction between innate factors or genetic hereditary with environmental factors [21–23].

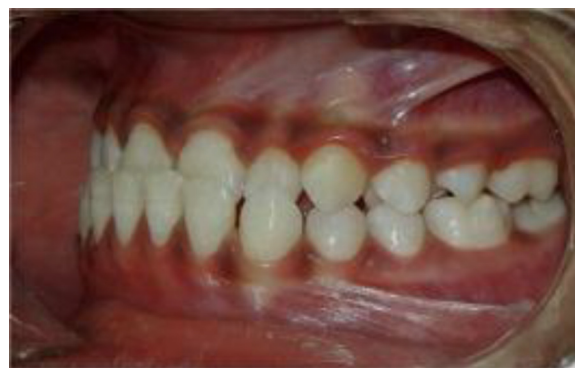

Fig. 1. Angle class III malocclusion (there is a mesial occlusion of the lower arch).

Studies of human inheritance have provided sufficient evidence to establish the fact that mandibular growth is mainly affected by heredity [23–27]. Familiar genetic inheritance has a strong influence on skeletal craniofacial dimensions contributing to Class III malocclusion and a significantly higher incidence of this malocclusion has been found to have a familial occurrence between members of many generations [28, 29]. The best known example of familial inheritance is Habsburg Jaw, in which mandibular prognathism recurred over multiple generations in the European royalty [30, 31]. The pattern of transmission of Class III malocclusion still remains an issue of controversy. According to some authors, the transmission is autosomal recessive, and according to others, it is autosomal dominant with complete or incomplete penetrance; yet, some others support the polygenic transmission mode [32, 33].

Environmental factors known to contribute and influence this malocclusion include wrong postural habits of the mandible which pathologically alter the mandibular condyle positioning within the fossa and as a result the final mandibular spatial position expressed with a forward slide of the mandible. Various factors such as growth stimulus, history of prolonged sucking or resting tongue habits, atypical swallowing, nasal airway obstruction, mouth breathing, functional mandibular shifts because of respiratory needs, tongue size and pharyngeal airway shape and size altered (enlarged tonsils, large tongue, adenoids), hormonal imbalances and disturbances such as gigantism or pituitary adenomas, trauma, premature loss of primary teeth, congenital anatomic defects (i.e. cleft lip, cleft palate), and muscle dysfunction alone or in combination with other environmental factors play a definitive etiological role [34–39].

## 4. Prevalence

Class III malocclusion compared with Class II or Class I malocclusion is a less frequently observed

clinical problem; occurring in less than 5% of the U.S. population. The prevalence is greater in Asian populations. The estimated incidence of Class III malocclusion among the Korean, Japanese, and Chinese is 4% to 14% because of the large percentage of patients with maxillary deficiency [7–9]. However, a study on Chinese children age 9 to 15 years that divided subjects into those with “pseudo” and “true” Class III malocclusions found a much lower prevalence of these disorders, 2.3% and 1.7%, respectively [40].

As for the components of Class III malocclusion, a study of Class III surgical patients demonstrated that the combination of underdeveloped maxilla and overdeveloped mandible was most common at 30.1%, whereas those with a normal maxilla and overdeveloped mandible constituted 19.2% of the sample. Most Korean patients, however, had a normal maxilla and overdeveloped mandible (47.7%), with fewer patients having an underdeveloped maxilla and overdeveloped mandible (13.5%) [40].

## 5. Treatment timing

It is an accepted fact that skeletal Class III malocclusion establishes itself early in life, is not a self-correcting disharmony [41, 42], and is often associated with maxillary constriction. Intervention at an early stage, such as deciduous dentition, or prepubertal growth phase has been recommended [43, 44]. In particular, the prepubertal treatment of Class III malocclusion by means of rapid palatal expansion and facemask protraction yields favorable growth corrections in both in maxilla and in the mandible [43]. The main goals of early intervention are to create a more favorable environment for growth and to improve the occlusal relationship: for example, correcting the crossbite and facial esthetics [45]. Hence, interceptive treatment of Class III malocclusions should be undertaken if it prevents damage to the oral tissues and prevents or significantly reduces the amount, or severity, of future orthodontic and surgical intervention [46].

Growth modification in developing Class III malocclusion is indicated in patients with skeletal discrepancy. The basic aim of interceptive treatment for developing Class III malocclusion is to improve or correct the skeletal discrepancy to allow future treatment of such patients by orthodontic camouflage only, without the need for orthognathic surgery. This approach of growth modification in Class III patients can be achieved through the use of functional appliances, chin cup therapy, protraction facemask, and bone-anchored appliances. A brief description of each modality based on current evidence has been given below [47].

The timing of treatment for Class III malocclusion has long been a matter of debate among orthodontists. The treatment should start early in the patient's childhood or the clinicians should wait until growth is completed and then proceed with orthognathic surgery. Some authors support the benefits of early treatment and point to the disadvantages of a long treatment time while waiting for a child's skeletal maturation before recommending orthognathic surgery. Others choose early orthognathic surgery because of concerns about dental compensation and/or mistiming of the cessation of mandibular growth during orthopedic treatment [48].

Baccetti *et al.* studied a sample of 46 subjects in mixed dentition and compared them to a control sample of 32 subjects with untreated Class III malocclusion. Treated and untreated samples were divided into early and late mixed dentition groups for identification of the optimum treatment timing. The younger group showed significantly greater advancement of maxillary structures and significantly more upward and forward direction of condylar growth after treatment [49]. In 2000 Saadia and Torres examined the sagittal response of Class III patients in the primary, mixed, and late mixed dentition phases who were treated with expansion followed by facemask therapy. They found that greater significant changes were seen in patients treated in the primary and mixed dentition phases, even with fewer hours of appliance wear per day. Looking at all of these results, it seems favorable to apply maxillary protraction before the age of 12 years. Nevertheless, the treatment results are more effective when maxillary protraction is initiated at an early developmental phase of the dentition rather than at later stages [50].

## 6. Orthodontic appliances

The options for correction of Class III malocclusion in growing patients consist of two principal categories: intraoral and extraoral appliances.

### 6.1. Intra oral appliances

#### 6.1.1. Class III elastics with skeletal anchorage

Recently, the use of skeletal anchorage for the orthopedic treatment of maxillary retrognathia has increased in order to avoid the dentoalveolar and skeletal side effects of tooth-borne devices and also to enhance maxillary protraction. Four miniplates are inserted in the left and right infrazygomatic crest of the maxillary buttress and between the lower left and right lateral incisors and canines. A mucoperiosteal flap is elevated and the miniplates are placed in the underlying bone by miniscrews.

The extension of the plates perforates the attached gingiva, and they are loaded three weeks later with Class III elastics [51]. Skeletal anchorage is used in skeletal Class III patients with hypoplasia of the maxilla determined by cephalometric analysis and soft tissue profile evaluation, in addition to presenting molar Class III and negative overjet. These patients must be between the ages of 9 and 14 years in a pre-pubertal period [52].

#### 6.1.2. Bionator III

The reverse Bionator or Bionator III is a modified version of the traditional bionator and can be used in the treatment of Class III malocclusion. The modified Bionator differs in various characteristics from the original appliance [53]. The lingual wire is in a different position to control the position of the tongue up to the upper first molar. The labial arch is placed in the middle of the lower teeth. The acrylic should be made as small as possible in order to occupy minimal space and should have a concave form to accommodate the tongue. The vertical occlusal height should be enough to correct the anterior crossbite, but should not exceed 3–4 mm. The construction bite is taken by positioning the mandible posteriorly into centric relation. Finally, the acrylic vestibular lateral shields should be positioned to allow lateral alveolar growth in order to permit expansion of the maxillary arch. The patients all wore the Bionator approximately 15 hours daily for a period of 60–90 days. At the end of this period in all cases the correction of anterior crossbite and the elimination of the mandibular displacement were obtained, but the use of a Class III Bionator was continued for a further period to maximize the chances of stability [54].

#### 6.1.3. Frankle III functional appliance

Frankel III functional appliance is made while the mandible is positioned posteriorly. The device has pads to stretch the upper lip and periosteum forward, which stimulates forward growth of maxilla [55]. The Frankel III appliance requires a lengthy treatment time and excellent patient cooperation. The Frankel III appliance can be very effective if the case is diagnosed early. The biggest problem is patient cooperation. At the same time, it does not allow the mandible to advance forward. The vertical opening of the appliance is used to enhance the downward and forward eruption of the maxillary posterior teeth [56].

#### 6.1.4. Eschler appliance

The Eschler appliance consists of 3 parts. The first part is a retention component such as Adams clasps for molars and intermolar auxiliary clasps for deciduous teeth and premolars. The second part is an Eschler

labial bow made of a 0.9 mm wire. The third part is occlusal bite raising, made of acrylic resin measuring 2–3 mm in thickness. An expansion screw or spring can be added for some specific purposes [57].

#### 6.1.5. Double-plate appliance

The double-plate appliance is an intraoral appliance containing angulated acrylic blocks, with an acrylic segment that contacts the lingual surfaces of lower incisors in order to prevent their retraction [58]. This appliance used for treatment of skeletal class III [mandibular protrusion]. By using the forces, especially suitable for children in the early transitional dentition of the facial muscles, also can be an alternative to extra-oral devices e.g. Chin- Cap and Face mask and can be used as retainer and tongue-lifter at the same time [59].

#### 6.1.6. Tandem appliance

The Tandem appliances are made up of three components. The upper appliance is fixed, with bands on deciduous second molars, a transpalatal arch, and palatal expansion arms and buccal arms for elastic traction. The lower appliance has bands on the deciduous second molars, a lingual holding arch, a fixed bite plane for posterior occlusal coverage, and buccal face bow tubes. The outer bow of the headgear face bow has been modified to engage elastics and is inserted into the lower tubes [60].

### 6.2. Extra oral appliance

#### 6.2.1. Chin cap

Chin cap is a useful appliance in growing patients that exhibit mandibular prognathism and short lower facial height. It has been shown that chin cap redirects mandibular growth, rotates the mandible backward, retards mandibular growth, and remodels the mandible. It also increases the anterior facial height. It is particularly more useful for Asian children compared to Caucasians, which is attributed to their shorter facial height and greater protrusion of lower incisors, rather than to differences in their response to treatment [55]. The objective of early treatment with the use of a chin cup is to provide growth inhibition or redirection and posterior positioning of the mandible [61].

#### 6.2.2. Headgear for mandibular arch

Baccetti *et al.* and Rey *et al.* used the mandibular cervical headgear in growing Class III patients exhibiting mandibular prognathism. This treatment option results in distalization of mandibular molars and redirection of mandibular growth [62, 63]. Orthodontic fixed appliance therapy in combination

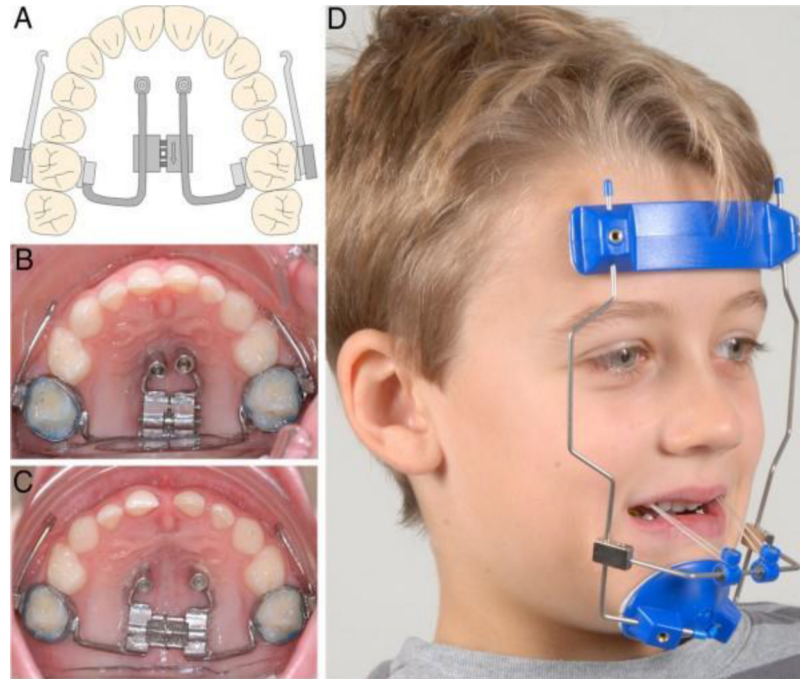


Fig. 2. Face mask of Petit type combined with maxillary skeletal expansion using orthodontic miniscrews.

with a reverse pull headgear for the correction of Class III malocclusion is believed to be more effective in early-mixed dentition as compared to late-mixed dentition. Hence, the orthopedic correction of skeletal Class III malocclusion with the help of a reverse pull headgear in a growing patient is crucial as it aids in achieving a better esthetic profile and reduces the chances of further surgical treatment to correct the skeletal discrepancy [64].

#### 6.2.3. Face masks

Orthopedic protraction of maxilla in Class III patients exhibiting maxillary retrusion and meso- or brachyfacial patterns proved effective [60, 61]. The most effective appliance in such cases is a face mask. However, there are some limitations in the use of a face mask, including patient compliance problems, dentoalveolar effect, limited protraction of maxilla (2–3 mm in 9–12 months), and the possibility of relapse as a result of mandibular growth [65–69] Fig. 2.

Face masks have various clinical applications. The clinician may choose a Petit face mask or a Delaire type as an extraoral part of the appliance, opt for skeletal anchorage versus dental anchorage, or choose advancement with expansion in contrast to advancement without expansion. Delaire face mask is commonly used for protraction of maxilla. The chin and forehead are used for extraoral anchorage [70]. This appliance might interfere with sleep or wearing eyeglasses [55]. Petit modified the Delaire face mask

in 1983, incorporating a forehead and a chin pad that were connected with a heavy steel rod [71].

#### 6.2.4. Protraction of maxilla with expansion & without expansion

Use of rapid maxillary expansion (RME) has been recommended for protraction of maxilla. Some authors believe that expansion will disarticulate maxilla and initiate cellular response [72–74]. The appliance in the maxillary arch is a bonded or banded maxillary expander. The patient activates the expander once or twice a day until the desired transverse relationship is achieved [52]. Another protocol is the use of alternate rapid maxillary expansions and constrictions (Alt-RAMEC). Activation of expansion/constriction is 0.5 mm daily [75] to disarticulate the suture without overexpansion [76, 77].

#### 6.2.5. Face mask with dental anchorage

A routine protocol for face mask therapy is application of force to a removable appliance in the maxilla. There is consensus over application of force at 30° angulation to the occlusal plane for minimum unwanted rotation of the maxilla. Forces of 300–600 g on each side are favorable. The skeletal results obtained with different amounts of force (300–500 g) are similar, resulting in 3° increase in SNA [78].

#### 6.2.6. Protraction face mask and reverse twin block

Early treatment of Class III malocclusions with protraction face mask and reverse twin block (PFM and

RTB) might be effective. The remaining growth will influence the long-term stability of these treatments [79].

#### 6.2.7. Face mask with skeletal anchorage: Bone Anchor Maxillary Protraction (BAMB)

- (1) *Face Mask with a Titanium Screw.* Titanium screws have been successfully used as skeletal anchorage [80]. These screws do not require latency time for osseointegration, and treatment can be instituted immediately after insertion. In a case report, a lag titanium screw was applied as skeletal anchorage for protraction of maxilla. 800 g force per side was applied at a 30° angle relative to the occlusal plane. The anterior nasal spine was advanced approximately 3 mm anteriorly, with stable improvement after a year [81].
- (2) *Face Mask with Onplant.* In 1995 Block and Hoffman applied onplant as anchorage for orthodontic purposes in animals [82]. The onplants were reported to tolerate forces up to 300 g. In a different study, onplants were used for application of force to the maxilla. Subsequent to a surgical operation for insertion of onplants (7.7 mm hexagonal onplants) near the molar area, a vacuum-formed stent was used for 10 days. Osseointegration occurred over a period of 3–4 months. Then a 400 g force per side was transmitted to the hooks in the premolar area of the maxillary fixed appliance. The onplants, as a reference point, moved 2.9 mm horizontally and 2.9 mm vertically over a 12-month period [83].
- (3) *Face Mask with Osseointegrated Implants.* The first clinical use of titanium implants as an anchorage for maxillary protraction occurred in an animal study. These Brånemark implants withstood 600 g force per side and an 8 mm advancement of the maxilla was achieved [84]. In a different study, implants were used in the zygomatic process of the maxilla and a 400 g force per side was applied, resulting in a 4 mm advancement of the maxilla [85].
- (4) *Face Mask to an Ankylosed Primary Canine.* The use of an intentionally ankylosed tooth is a proper technique for the direct transmission of force for protraction of the maxilla. However, such teeth undergo resorption as their permanent successors erupt, restricting the use of ankylosed teeth to young patients [86].

#### 6.2.8. Corticotomy-assisted maxillary protraction

Low-angle Class III patients who exhibit severe retrognathism of the maxilla, patients who have lost the chance of orthopedic correction, and patients

who refuse to undergo orthognathic surgeries are candidates for corticotomy-assisted maxillary protraction [87]. Sutural distraction osteogenesis versus osteotomy distraction osteogenesis for protraction of midface has already been used. Lefort III fractures have been used in the zygomaticofrontal suture. Distraction has been carried out with the use of heavy elastics [88]. Rachmiel *et al.* in 1999 [89] and Samchukov in 2001 [90] reported patients treated by an incomplete Lefort I osteotomy followed by face mask protraction. They reported 5–9 mm of maxillary protraction. In such a treatment modality a face mask is used for 5–7 days after surgery and a 1700–2000 g force is applied. Significant relapse of maxillary advancement was detected in a 6-year follow-up. However, well-preserved dental relationship was reported [91].

## 7. Discussion

Orthopedic treatments might prove effective in children with Class III malocclusion in the short term [92]. Several appliances are used for early treatment of skeletal Class III, including Bionator [93], Frankel (FR-III) [55], chin cup [61], double-plate appliance [59], Eschler appliance “progenic appliance” [94], and protraction face mask. Orthopedic protraction of the maxilla is a popular treatment modality, with some limitations, including problems with patient compliance, limited protraction of the maxilla (2–3 mm in 9–12 months), unwanted dentoalveolar effects, and the possibility of relapse as a result of late mandibular growth [68, 69, 95]. In addition, rapid maxillary expansion (RME) has been recommended as a routine component of treatment for correction of Class III malocclusion, even in the absence of maxillary constriction because it disarticulates the maxilla and gives rise to cellular responses in the circummaxillary sutures, bringing about a more positive reaction to protraction forces [96]. Nevertheless, when used to enhance anterior movement of the maxilla during face mask therapy, preliminary RME does not appear to exert any effect on the efficacy of orthopedic treatment [95]. There are reports that use of RME alone might not properly disarticulate circummaxillary sutures and it might be better dealt with by Alt-RAMEC [98].

Face mask therapy is effective in Class III, maxillary-deficient, deep-bite patients, and all the treated patients exhibit positive overjet after treatment. In a study, after face mask therapy, the maxilla continued to grow in the anterior direction in an amount 9+9+equal to untreated Class III patients but less than that in untreated Class I patients; mandibular growth was similar in all the groups [99].

An important factor determining the success of treatment for Class III patients is treatment timing. It has been recommended that face mask therapy should be initiated at 6–8 years of age after eruption of maxillary permanent first molar and incisors, that is, early mixed dentition. However, maxillary protraction with bone anchors and Class III elastics has been reported to be successful in the late mixed or permanent dentition phases [100].

## 8. Conclusion

Even though there are multiple and powerful treatment possibilities; face mask is the common and most effective treatment option for skeletal class III malocclusion before maxillary sutures maturation, if it is initiated during the early mixed dentition phase. However, maxillary protraction with bone anchors and Class III elastics has been reported to be successful in the late mixed dentition years.

## References

1. International Journal of Orthodontia and Oral Surgery, Milo Hellman D.D.S., Sc.D., February 1937;23(2):120–148.
2. Perillo L. Early treatment of dentoskeletal Class III malocclusion: SEC III protocol. *APOS Trends Orthod.* 2019;9(2):73–76.
3. Khan MB, Karra A. Early treatment of class III malocclusion: a boon or a burden? *International Journal of Clinical Pediatric Dentistry.* 2014;7:130–136.
4. Cevidanes L, Baccetti T, Franchi L, McNamara JA Jr., De Clerck H. Comparison of two protocols for maxillary protraction: bone anchors versus face mask with rapid maxillary expansion. *Angle Orthod.* 2010;80(5):799–806. View at: Publisher Site | Google Scholar.
5. Celikoglu M, Oktay H. Effects of maxillary protraction for early correction of class III malocclusion. *Eur J Orthod.* 2014;36(1):86–92. View at: Publisher Site | Google Scholar
6. De Clerck HJ, Proffit WR. Growth modification of the face: a current perspective with emphasis on Class III treatment. *Am J Orthod Dentofacial Orthop.* 2015;148(1):37–46.
7. Fu M, Zhang D, Wang B, Deng Y, Wang F, Ye X. The prevalence of malocclusion in China—an investigation of 25,392 children. *Chin J Stomatol.* 2002;37(5):371–373.
8. Irie M, Nakamura S. Orthopedic approach to severe skeletal Class III malocclusion. *Am J Orthod.* 1975;67(4):377–392.
9. Bukhary MT. Comparative cephalometric study of Class III malocclusion in Saudi and Japanese adult females. *J Oral Sci.* 2005;47(2):83–90.
10. Mouakeh M. Cephalometric evaluation of craniofacial pattern of Syrian children with Class III malocclusion. *Am J Orthod Dentofacial Orthop.* 2001;119(6):640–649.
11. Celikoglu M, Akpınar S, Yavuz I. The pattern of malocclusion in a sample of orthodontic patients from Turkey. *Medicina Oral, Patologia Oral y Cirugia Bucal.* 2010;15(5):791–e796.
12. Ishii I, Morita S, Takeuchi Y, Nakamura S. Treatment effect of combined maxillary protraction and chin cup appliance in severe skeletal Class III cases. *Am J Orthod Dentofacial Orthop.* 1987;92(4):304–312.
13. Textbook of Orthodontics, Second Edition, Dr. V Surendra Shetty ©2007, Gurkeerat Sing.
14. Jamilian A, Cannavale R, Pincino MG, Eslami S, Perillo L. Methodological quality and outcome of systematic reviews reporting on orthopaedic treatment for class III malocclusion: Overview of systematic reviews. *J Orthod.* 2016;43:102–120. [PubMed] [Google Scholar]
15. Perillo L, Vitale M, Masucci C, D'Apuzzo F, Cozza P, Franchi L, et al. Comparisons of two protocols for the early treatment of class III dentoskeletal disharmony. *Eur J Orthod.* 2016;38:51–56. [PubMed] [Google Scholar]
16. Perillo L, Monsurrò A, Bonci E, Torella A, Mutarelli M, Nigro V, et al. Genetic association of ARHGAP21 gene variant with mandibular prognathism. *J Dent Res.* 2015;94:569–76. [PubMed] [Google Scholar]
17. Perillo L, Masucci C, Ferro F, Apicella D, Baccetti T. Prevalence of orthodontic treatment need in southern Italian schoolchildren. *Eur J Orthod.* 2010;32:49–53. [PubMed] [Google Scholar]
18. Ferro A, Nucci LP, Ferro F, Gallo C. Long-term stability of skeletal class III patients treated with splints, class III elastics, and chin cup. *Am J Orthod Dentofacial Orthop.* 2003;123:423–434. [PubMed] [Google Scholar]
19. British Standards Institute. Glossary of Dental Terms (BS 4492). London: BSI; 1983.
20. Graber TM, Vanarsdall RL Jr., Katherine WL. Orthodontics. Current principles & techniques, 4th edition. The European Journal of Orthodontics. 2005;28(2):565. doi: 10.1093/ejo/cji127.
21. Kawala B, Antoszewska J, Necka A. Genetics or environment? A twin-method study of malocclusions. *World J Orthod.* 2007;8(4):405–410. [PubMed] [Google Scholar]
22. Watnick SS. Inheritance of craniofacial morphology. *Angle Orthod.* 1972;42(4):339–351. [PubMed] [Google Scholar]
23. Jena AK, Duggal R, Mathur VP, Parkash H. Class-III malocclusion: genetics or environment? A twins study. *J Indian Soc Pedod Prev Dent.* 2005;23(1):27–30. [PubMed] [Google Scholar]
24. Litton SF, Ackermann LV, Isaacson RJ, Shapiro BL. A genetic study of class III malocclusion. *Am J Orthod.* 1970;58(6):565–577. [PubMed] [Google Scholar]
25. Marković M. Results of a genetic study of triplets with class III malocclusion. *Zahn Mund Kieferheilkd Zentralbl.* 1983;71(2):184–190. [PubMed] [Google Scholar]
26. Mossey PA. The heritability of malocclusion: part 1—genetics, principles and terminology. *Br J Orthod.* 1999;26(2):103–113. [PubMed] [Google Scholar]
27. Harris JE, Kowalski CJ, Watnick SS. Genetic factors in the shape of the craniofacial complex. *Angle Orthod.* 1973;43(1):107–111. [PubMed] [Google Scholar]
28. Nakasima A, Ichinose M, Nakata S, Takahama Y. Hereditary factors in the craniofacial morphology of Angle's Class II and Class III malocclusions. *Am J Orthod.* 1982;82(2):150–156. [PubMed] [Google Scholar]
29. Mossey PA. The heritability of malocclusion: part 2. The influence of genetics in malocclusion. *Br J Orthod.* 1999;26(2):195–203. [PubMed] [Google Scholar]
30. Hodge GP. A medical history of the Spanish Habsburgs—as traced in portraits. *JAMA.* 1977;238(11):169–174. [PubMed] [Google Scholar]
31. Chudley AE. Genetic landmarks through philately—the Habsburg jaw. *Clin Genet.* 1998;54(4):283–284. [PubMed] [Google Scholar]
32. Huang CM, Mi MP, Vogt DW. Mandibular prognathism in the rabbit: discrimination between single-locus and multifactorial models of inheritance. *J Hered.* 1981;72(4):296–298. [PubMed] [Google Scholar]
33. Cruz RM, Krieger H, Ferreira R, Mah J, Hartsfield J, Oliveira S. Major gene and multifactorial inheritance of mandibular prognathism. *Am J Med Genet A.* 2008;146A(1):71–77. [PubMed] [Google Scholar]
34. Rakosi T, Schilli W. Class III anomalies: a coordinated approach to skeletal, dental, and soft tissue problems. *J Oral Surg.* 1981;39(11):860–870. [PubMed] [Google Scholar]
35. Chung JC. Redirecting the growth pattern with rapid maxillary expander and chin cup treatment: changing breathing pattern from oral to nasal. *World J Orthod.* 2006;7(3):236–253. [PubMed] [Google Scholar]

36. Harris EF. Size and form of base of the skull in isolated cleft lip and palate. *Cleft Palate Craniofac J*. 1993;30(2):170-174. [PubMed] [Google Scholar]
37. Cortés J, Granic X. Características cranio-faciales chez un groupe de patients chiliens atteints de fente labio-maxillo-palatine unilatérale opérée. [Characteristic craniofacial features in a group of unilateral cleft lip and palate patients in Chile. *Rev Stomatol Chir Maxillofac*. 2006;107(5):347-353. French. [PubMed] [Google Scholar]
38. Graber TM. The "three M's": muscles, malformation, and malocclusion. *Am J Orthod*. 1963;49(6):418-450. [Google Scholar]
39. Sugawara Y, Ishihara Y, Takano-Yamamoto T, Yamashiro T, Kamioka H. Orthodontic treatment of a patient with unilateral orofacial muscle dysfunction: the efficacy of myofunctional therapy on the treatment outcome. *Am J Orthod Dentofacial Orthop*. 2016;150(1):167-180. [PubMed] [Google Scholar]
40. Ngan P, He H, in *Current Therapy in Orthodontics*, 2010.
41. Mitani H, Sato K, Sugawara J. Growth of mandibular prognathism after pubertal growth peak. *Am J Orthod Dentofacial Orthop*. 1993;104(4):330-336.
42. Baccetti T, Reyes BC, McNamara JA. Craniofacial changes in Class III malocclusion as related to skeletal and dental maturation. *Am J Orthod Dentofacial Orthop*. 2007;132(2):171.e1-171.e12.
43. Westwood PV, McNamara JA, Baccetti T, Franchi L, Sarver DM. Long-term effects of Class III treatment with rapid maxillary expansion and facemask therapy followed by fixed appliances. *Am J Orthod Dentofacial Orthop*. 2003;123(3):306-320.
44. Cha K-S. Skeletal changes of maxillary protraction in patients exhibiting skeletal Class III malocclusion: a comparison of three skeletal maturation groups. *Angle Orthod*. 2003;73(1):26-35.
45. Campbell PM. The dilemma of Class III treatment. Early or late? *Angle Orthod*. 1983;53(3):175-191.
46. Turpin DL. Early Class III treatment. Presented at: 81st Annual Session, American Association of Orthodontists; San Francisco: 1981. [Google Scholar]
47. Developing Class III malocclusions: challenges and solutions Edlira Zere, Prabhat Kumar Chaudhari, and Nitesh Tiwari Published online 2018 Jun 22.
48. *Esthetics and Biomechanics in Orthodontics*. Second Edition, Ravindra Nanda, Copyright ©2015 by Saunders, an imprint of Elsevier Inc.
49. Baccetti T, McGill JS, Franchi L, McNamara JA Jr, Tollaro I. Skeletal effects of early treatment of Class III malocclusion with maxillary expansion and face-mask therapy. *Am J Orthod Dentofacial*. 1998;113:333-343.
50. Saadia M, Torres E. Sagittal changes after maxillary protraction with expansion in class III patients in the primary, mixed, and late mixed dentitions: a longitudinal retrospective study. *Am J Orthod Dentofacial Orthop*. 2000;117(6):669-680.
51. Cevdanes L, Baccetti T, Franchi L, McNamara JA Jr, De Clerck H. Comparison of two protocols for maxillary protraction: bone anchors versus face mask with rapid maxillary expansion. *Angle Orthod*. 2010;80(5):799-806. View at: Publisher Site | Google Scholar.
52. De Clerck HJ, Proffit WR. Growth modification of the face: A current perspective with emphasis on Class III treatment. *Am J Orthod Dentofacial Orthop*. 2015;148:37-46. <http://dx.doi.org/10.1016/j.ajodo.2015.04.017> | Medline.
53. Levrini A, Levrini L. Il Bionator concetti classici e nuove acquisizioni. *Riv Ital Stomatol*. 1993;10:499-506. View at: Google Scholar.
54. Garattini G, Levrini L, Crozzoli P, Levrini A. Skeletal and dental modifications produced by the Bionator III appliance. *Am J Orthod Dentofacial Orthop*. 1998 ;114(1):40-44. View at: Google Scholar.
55. Proffit WR, Fields HW Jr., Sarver DM. *Contemporary Orthodontics*, Elsevier Health Sciences, Philadelphia, Pa, USA, 2014.
56. Miethke RR, Lindenau S, Dietrich K. The effect of Penkel's function regulator type 111 on the apical base. *Eur J Orthod*. 2002;25:11-318.
57. De Almeida MR, De Almeida RR, Oltramari-Navarro PVP, Conti ACD, Navarro RDL, Camacho JGDD. Early treatment of Class III malocclusion: 10-year clinical follow-up. *J Appl Oral Sci*. 2011;19(4):431-439. View at: Publisher Site | Google Scholar.
58. Gencer D, Kaygisiz E, Yüksel S, Tortop T. Comparison of double-plate appliance/facemask combination and facemask therapy in treating Class III malocclusions. *Angle Orthod*. 2015;85(2):278-283. View at: Publisher Site | Google Scholar.
59. Sander FG. Dentale und skelettale Effekte bei der Anwendung der Rückschubdoppelplatte (SIII) für die Klasse-III-Behandlung. *Inf Orthod Kieferorthop*. 2001;34(4):345-360.
60. Sukh R, Singh GP, Tandon P. A new modified tandem appliance for management of developing Class III malocclusion. *Contemp Clin Dent*. 2013;4(4):515-519. View at: Publisher Site | Google Scholar.
61. Sugawara J, Asano T, Endo N, Mitani H. Long-term effects of chin cap therapy on skeletal profile in mandibular prognathism. *Am J Orthod Dentofacial Orthop*. 1990;98(2):127-133. View at: Publisher Site | Google Scholar.
62. Baccetti T, Rey D, Angel D, Oberti G, McNamara JA Jr. Mandibular cervical headgear vs rapid maxillary expander and facemask for orthopedic treatment of class III malocclusion. *Angle Orthod*. 2007;77(4):619-624. View at: Publisher Site | Google Scholar.
63. Rey D, Aristizabal JF, Oberti G, Angel D. Mandibular cervical headgear in orthopedic and orthodontic treatment of Class III cases. *World J Orthod*. 2006;7(2):165-176. View at: Google Scholar.
64. Staggers JA, Germane N, Legan HL. Clinical considerations in the use of protraction headgear. *J Clin Orthod*. 1992;26:87-91. [Google Scholar].
65. Baccetti T, McGill JS, Franchi L, McNamara JA Jr., Tollaro I. Skeletal effects of early treatment of Class III malocclusion with maxillary expansion and face-mask therapy. *Am J Orthod Dentofacial Orthop*. 1998;113(3):333-343. View at: Google Scholar.
66. Turley PK. Managing the developing class III malocclusion with palatal expansion and facemask therapy. *Am J Orthod Dentofacial Orthop*. 2002;122(4):349-352. View at: Publisher Site | Google Scholar.
67. Cha K-S. Skeletal changes of maxillary protraction in patients exhibiting skeletal class III malocclusion: a comparison of three skeletal maturation groups. *Angle Orthod*. 2003;73(1):26-35. View at: Google Scholar.
68. Kim J-H, Viana MA, Graber TM, Omerza FF, BeGole EA. The effectiveness of protraction face mask therapy: a meta-analysis. *Am J Orthod Dentofacial Orthop*. 1999;115(6):675-685. View at: Google Scholar.
69. Baccetti T, Franchi L, McNamara JA Jr. Cephalometric variables predicting the long-term success or failure of combined rapid maxillary expansion and facial mask therapy. *Am J Orthod Dentofacial Orthop*. 2004;126(1):16-22. View at: Publisher Site | Google Scholar.
70. Elai JD. La croissance maxillaire: deductions therapeutiques. 1971. View at: Google Scholar.
71. Petit H. "Adaptation following accelerated facial mask therapy," in *clinical Alteration of the Growing Face*. J. A. McNamara Jr., K. A. Ribbens, R. P. Howe, Eds., Monograph no. 14, Craniofacial Growth Series, pp. 253-289. Center for Human Growth and Development, University of Michigan, Ann Arbor, Mich, USA, 1983. View at: Google Scholar.
72. Turley PK. Orthopedic correction of Class III malocclusion with palatal expansion and custom protraction headgear. *J Clin Orthod*. 1988;22(5):314-325. View at: Google Scholar.

73. Altug Z, Arslan AD. Skeletal and dental effects of a mini maxillary protraction appliance. *Angle Orthod.* 2006;76(3):360–368. View at: [Google Scholar](#).
74. Canturk BH, Celikoglu M. Comparison of the effects of face mask treatment started simultaneously and after the completion of the alternate rapid maxillary expansion and constriction procedure. *Angle Orthod.* 2015;85(2):284–291. View at: [Publisher Site](#) | [Google Scholar](#).
75. Kaya D, Kocadereli I, Kan B, Tasar F. Effects of facemask treatment anchored with miniplates after alternate rapid maxillary expansions and constrictions; a pilot study. *Angle Orthod.* 2011;81(4):639–646. View at: [Publisher Site](#) | [Google Scholar](#).
76. Liou EJ-W. Effective maxillary orthopedic protraction for growing Class III patients: a clinical application simulates distraction osteogenesis. *Prog Orthod.* 2005;6(2):154–171. View at: [Google Scholar](#).
77. Liou EJ-W, Tsai W-C. A new protocol for maxillary protraction in cleft patients: repetitive weekly protocol of alternate rapid maxillary expansions and constrictions. *Cleft Palate Craniofac J.* 2005;42(2):121–127. View at: [Publisher Site](#) | [Google Scholar](#).
78. Yepes E, Quintero P, Rueda ZV, Pedroza A. Optimal force for maxillary protraction facemask therapy in the early treatment of class III malocclusion. *Eur J Orthod.* 2014;36(5):586–594. View at: [Publisher Site](#) | [Google Scholar](#).
79. Seehra J, Fleming PS, Mandall N, Dibiasi AT. A comparison of two different techniques for early correction of Class III malocclusion. *Angle Orthod.* 2012;82(1):96–101. View at: [Publisher Site](#) | [Google Scholar](#).
80. Creekmore TD, Eklund MK. The possibility of skeletal anchorage. *J Clin Orthod.* 1983;17(4):266–269. View at: [Google Scholar](#).
81. Enacar A, Giray B, Pehlivanoglu M, Iplikcioglu H. Facemask therapy with rigid anchorage in a patient with maxillary hypoplasia and severe oligodontia. *Am J Orthod Dentofacial Orthop.* 2003;123(5):571–577. View at: [Publisher Site](#) | [Google Scholar](#).
82. Block MS, Hoffman DR. A new device for absolute anchorage for orthodontics. *Am J Orthod Dentofacial Orthop.* 1995;107(3):251–258. View at: [Publisher Site](#) | [Google Scholar](#).
83. Hong H, Ngan P, Li HG, Qi LG, Wei SHY. Use of onplants as stable anchorage for facemask treatment: a case report. *Angle Orthod.* 2005;75(3):453–460. View at: [Google Scholar](#).
84. Sheller B, Omnell L. Therapeutic ankylosis of primary teeth. *J Clin Orthod.* 1991;25(8):499–502. View at: [Google Scholar](#).
85. Singer SL, Henry PJ, Rosenberg I. Osseointegrated implants as an adjunct to facemask therapy: a case report. *Angle Orthod.* 2000;70(3):253–262. View at: [Google Scholar](#).
86. Omnell ML, Sheller B. Maxillary protraction to intentionally ankylosed deciduous canines in a patient with cleft palate. *Am J Orthod Dentofacial Orthop.* 1994;106(2):201–205. View at: [Google Scholar](#).
87. Nevzatoğlu S, Küçükkeleş N. Long-term results of surgically assisted maxillary protraction vs regular facemask. *Angle Orthod.* 2014;84(6):1002–1009. View at: [Publisher Site](#) | [Google Scholar](#).
88. Liu C, Hou M, Liang L *et al.* Sutural distraction osteogenesis (SDO) versus osteotomy distraction osteogenesis (ODO) for midfacial advancement: a new technique and primary clinical report. *J Craniofac Surg.* 2005;16(4):537–548. View at: [Publisher Site](#) | [Google Scholar](#).
89. Rachmiel A, Aizenbud D, Ardekian L, Peled M, Laufer D. Surgically-assisted orthopedic protraction of the maxilla in cleft lip and palate patients. *International Journal of Oral and Maxillofacial Surgery.* 1999;28(1):9–14.
90. Nevzatoğlu S, Küçükkeleş N. Long-term results of surgically-assisted maxillary protraction. *Aust Orthod J.* 2014;30(1):19–31. View at: [Google Scholar](#).
91. Long H, Jian F, Lai W. Weak evidence supports the short-term benefits of orthopaedic treatment for Class III malocclusion in children. *Evid Based Dent.* 2014;15(1):21–22.
92. Levrini A, Levrini L. Il Bionator concetti classici e nuove acquisizioni. *Riv Ital Stomatol.* 1993;10:499–506.
93. de Almeida MR, de Almeida RR, Oltramari-Navarro PVP, Conti ACD, Navarro RDL, Camacho JGDD. Early treatment of Class III malocclusion: 10-year clinical follow-up. *Journal of Applied Oral Science.* 2011;19(4):431–439.
94. Yilmaz HN, Garip H, Satilmis T, Kucukkeles N. Corticotomy-assisted maxillary protraction with skeletal anchorage and Class III elastics. *Angle Orthod.* 2015;85(1):48–57.
95. Celikoglu M, Oktay H. Effects of maxillary protraction for early correction of class III malocclusion. *Eur J Orthod.* 2014;36(1):86–92. View at: [Publisher Site](#) | [Google Scholar](#).
96. Cordasco G, Matarese G, Rustico L *et al.* Efficacy of orthopedic treatment with protraction facemask on skeletal Class III malocclusion: a systematic review and meta-analysis. *Orthod Craniofac Res.* 2014;17(3):133–143. View at: [Publisher Site](#) | [Google Scholar](#).
97. Liou E-W, Tsai W-C. A new protocol for maxillary protraction in cleft patients: repetitive weekly protocol of alternate rapid maxillary expansions and constrictions. *Informationen aus Orthodontie & Kieferorthopädie.* 2007;39(4):267–274.
98. Macdonald KE, Kapust AJ, Turley PK. Cephalometric changes after the correction of class III malocclusion with maxillary expansion/facemask therapy. *Am J Orthod Dentofacial Orthop.* 1999;116(1):13–24. View at: [Google Scholar](#).
99. Cevidanes L, Baccetti T, Franchi L, McNamara JA Jr., De Clerck H. Comparison of two protocols for maxillary protraction: bone anchors versus face mask with rapid maxillary expansion. *Angle Orthod.* 2010;80(5):799–806.
100. Azamian Z, Shirban F. Treatment options for Class III Malocclusion in growing patients with emphasis on maxillary protraction. *Scientifica (Cairo).* 2016;2016:8105163. doi: [10.1155/2016/8105163](#).